

Schnyder Corneal Dystrophy

Category(ies): Cornea, Inherited Eye Disease

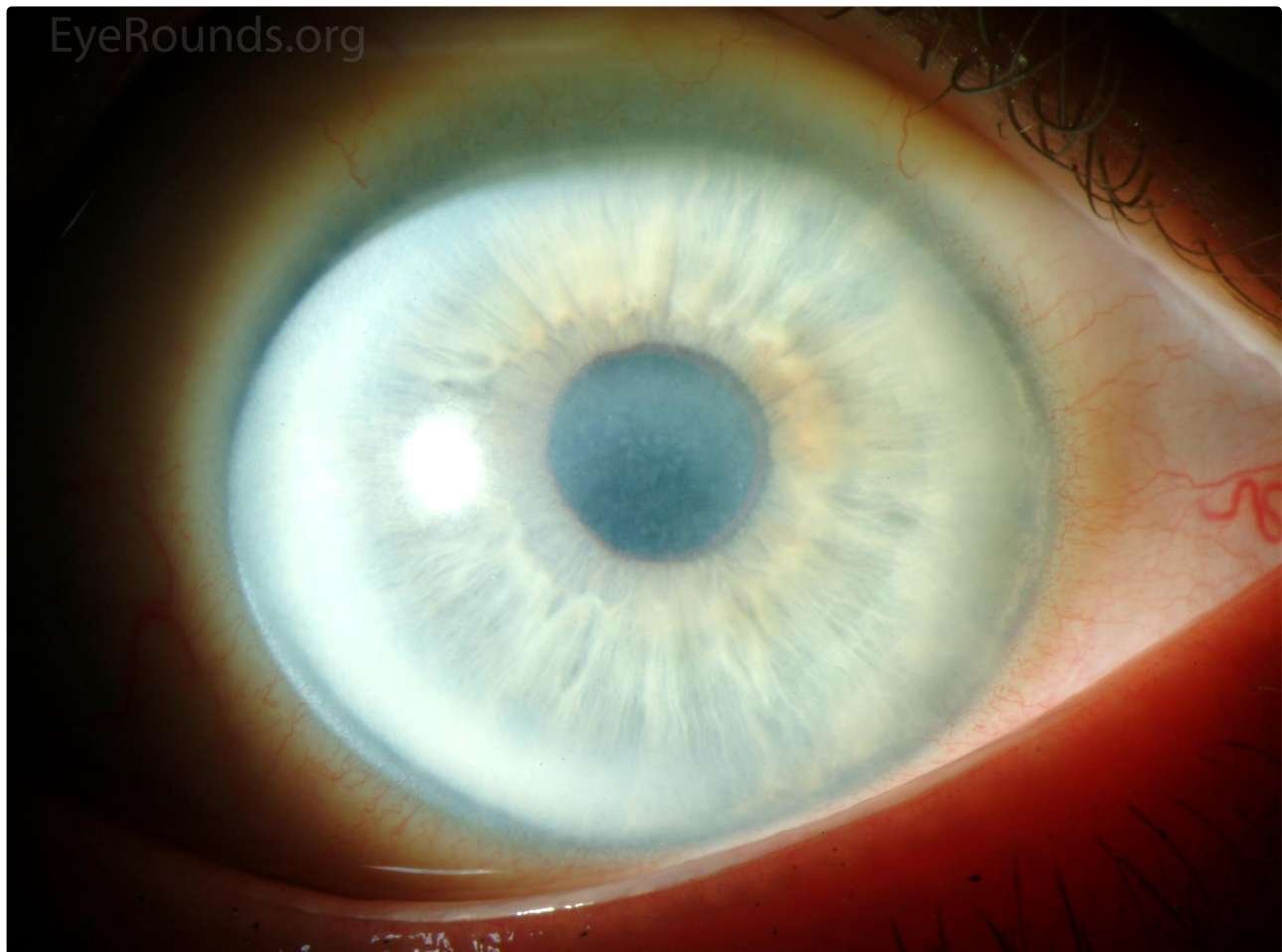
Contributor: [Jesse Vislisel, MD](#)

Photographer: Tracy Aly, CRA



Schnyder crystalline corneal dystrophy is an autosomal dominant condition caused by a mutation in the UbiA prenyltransferase domain-containing protein 1 (UVIAD1). It results in deposition of cholesterol and phospholipid crystals in the central corneal stroma. Later, the patients develop a dense corneal arcus, and eventually midperipheral corneal opacification and decreased corneal sensation.

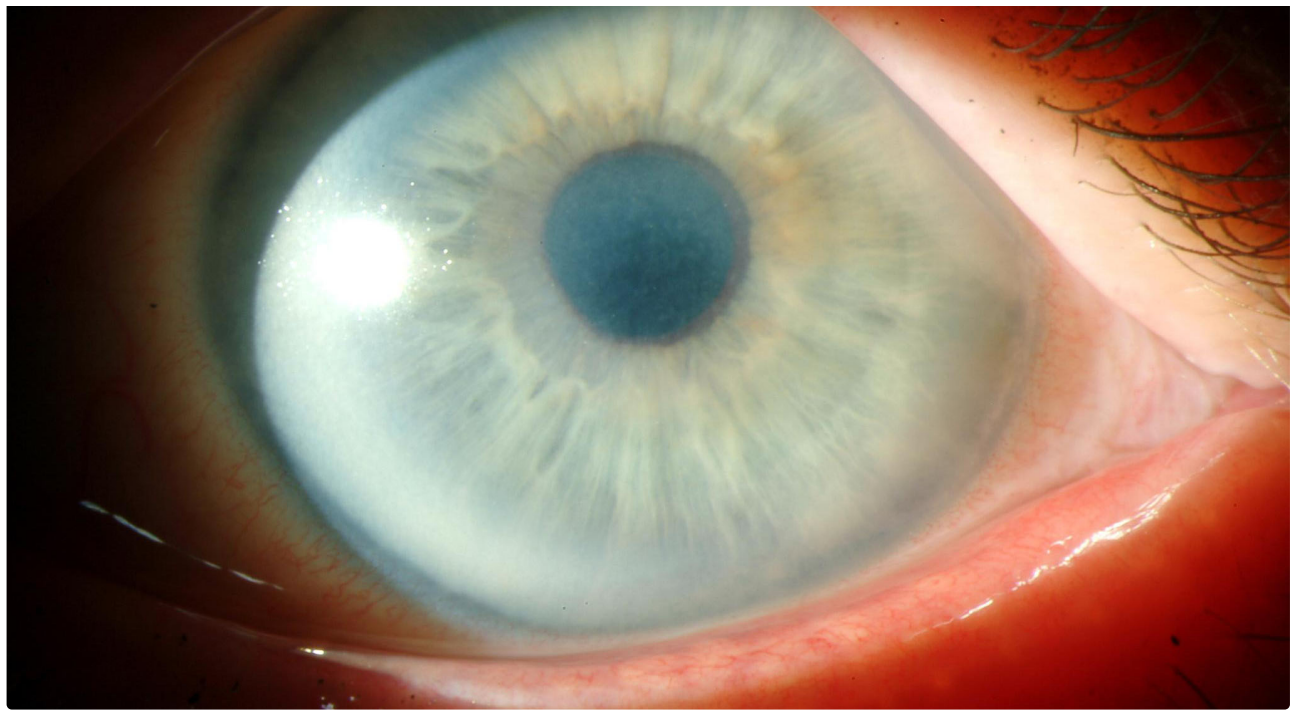
[OMIM #121800](#)



 Enlarge

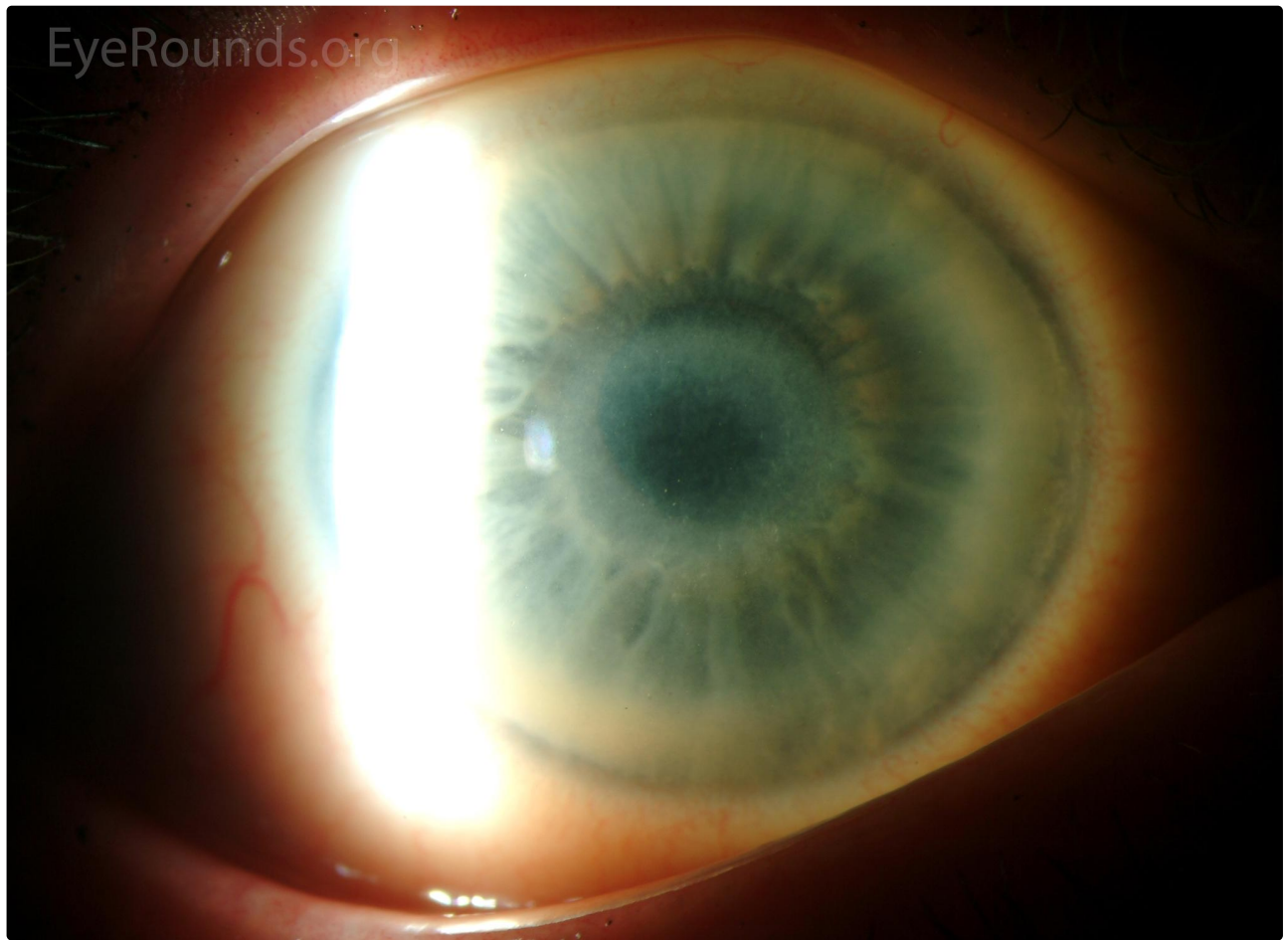
 Download





[Enlarge](#)

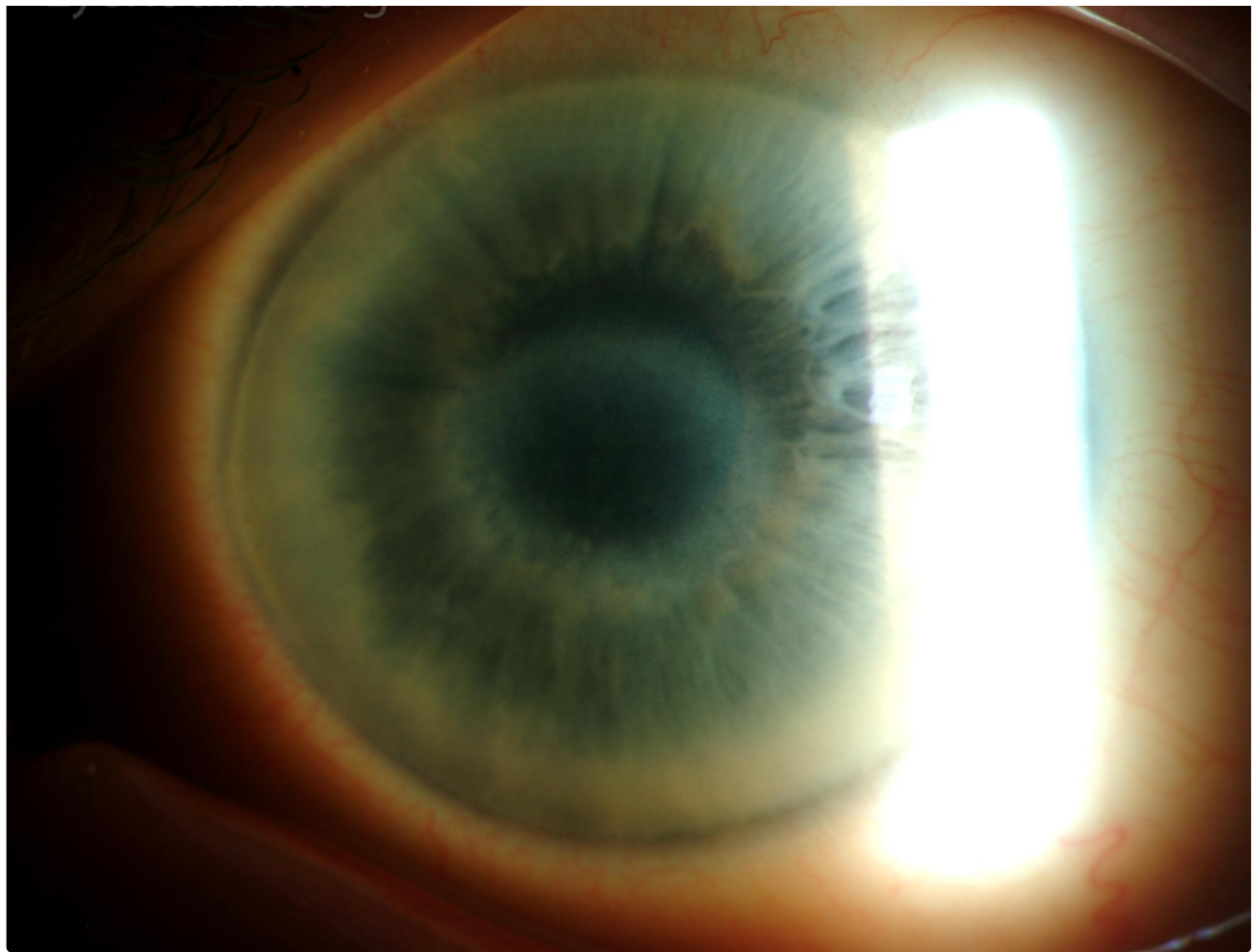
[Download](#)



[Enlarge](#)

[Download](#)







[Enlarge](#)

[Download](#)

EyeRounds.org

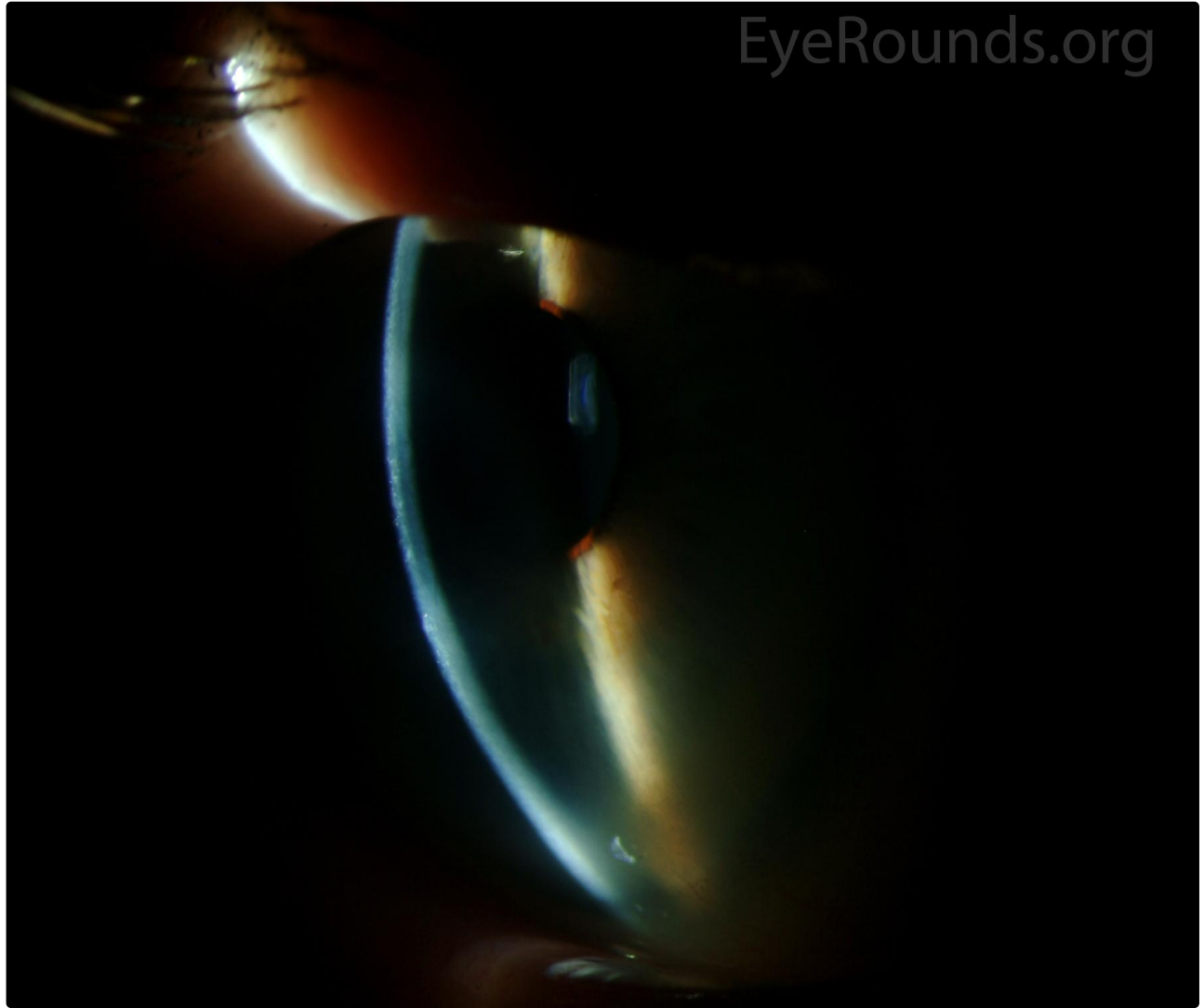




4/21/2006
10

[Enlarge](#)

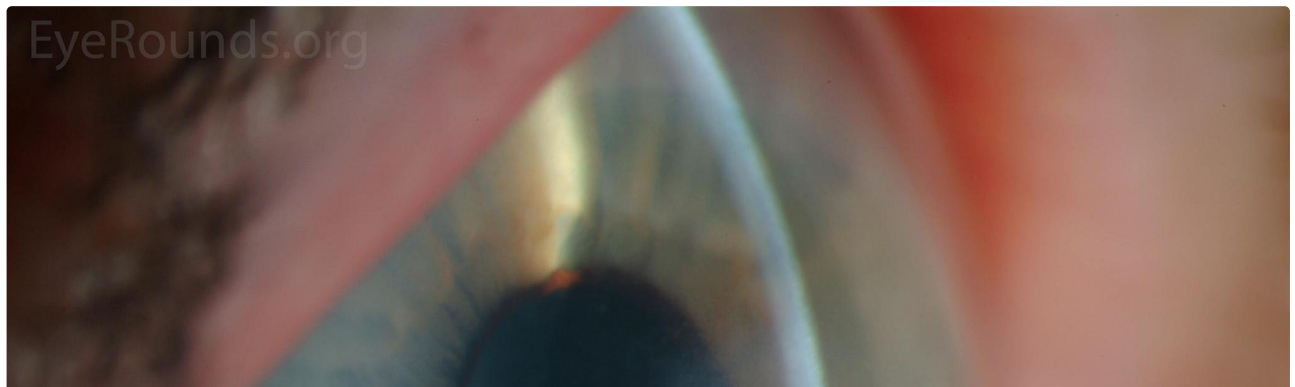
[Download](#)



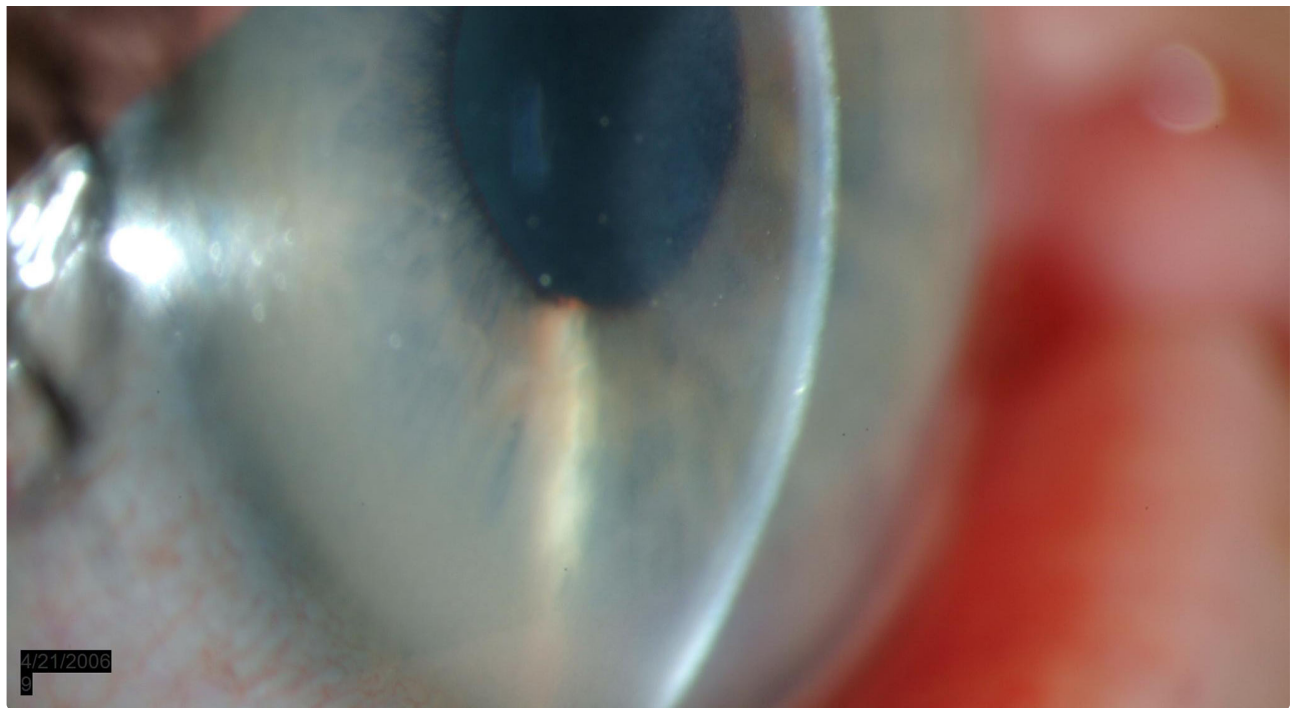EyeRounds.org

[Enlarge](#)

[Download](#)

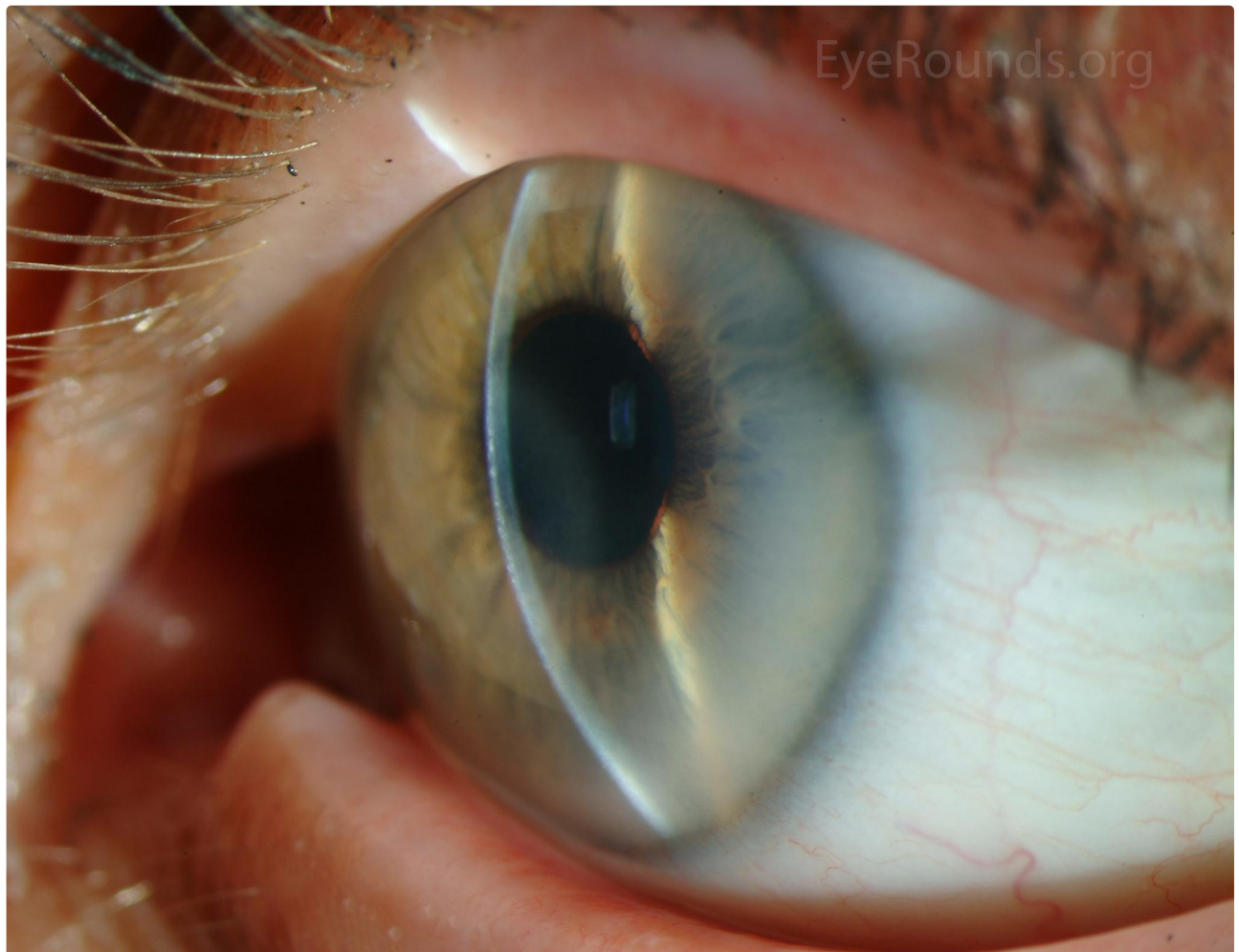


EyeRounds.org



[Enlarge](#)

[Download](#)



[Enlarge](#)

[Download](#)

Image Permissions:



Ophthalmic Atlas Images by EyeRounds.org, The University of Iowa are licensed under a [Creative Commons Attribution-NonCommercial-NoDerivs 3.0 Unported License](https://creativecommons.org/licenses/by-nc-nd/3.0/).

Address

University of Iowa
Roy J. and Lucille A. Carver College
of Medicine
Department of Ophthalmology and
Visual Sciences
200 Hawkins Drive
Iowa City, IA 52242

[Support Us](#)

Legal

Copyright © 2019 The University of
Iowa. All Rights Reserved
[Report an issue with this page](#)
[Web Privacy Policy](#) |
[Nondiscrimination Statement](#)

Related Links

[Cataract Surgery for Greenhorns](#)
[EyeTransillumination](#)
Gonioscopy.org
[Iowa Glaucoma Curriculum](#)
[Iowa Wet Lab](#)
[Patient Information](#)
[Stone Rounds](#)
[The Best Hits Bookshelf](#)

EyeRounds Social Media

Follow



[Receive notification of new cases,
sign up here](#)
[Contact Us](#)
[Submit a Suggestion](#)